

FOR OFFICIAL USE ONLY
Law Enforcement Sensitive

DEPARTMENT OF THE ARMY
U.S. ARMY CRIMINAL INVESTIGATION COMMAND
76th MP Det (CID), Camp Slayer, IZ APO AE 09342

MEMORANDUM FOR: SEE DISTRIBUTION

SUBJECT: CID REPORT OF INVESTIGATION - FINAL/SSI - 0209-2006-CID259-75994 - 5H6

DATES/TIMES/LOCATIONS OF OCCURRENCES:

1. 21 JUL 2006, 1400 - 21 JUL 2006, 1815; UNKNOWN LOCATION, SOUTHWEST OF MAHMUDIYAH, IRAQ

DATE/TIME REPORTED: 21 JUL 2006, 1745

INVESTIGATED BY:

SA (b)(6), (b)(7)(C), (b)(7)(F)
SA
SA

SUBJECT:

1. [CHANGE] UNKNOWN, ; [JUSTIFIABLE HOMICIDE] (NFI)

VICTIM:

1. UNKNOWN, (DECEASED); IRAQ; MALE; WHITE; XZ ; AKA: TAG NUMBER (b)(6), (b)(7)(C) ; [JUSTIFIABLE HOMICIDE] (NFI)

INVESTIGATIVE SUMMARY:

This is an Operation Iraqi Freedom Investigation.

This investigation was initiated after this office received notification by Sather Air Base Emergency Medical Services (EMEDS), Sather Air Base, Baghdad International Airport (BIAP), Baghdad, Iraq, APO AE 09342, that an unknown Iraqi male died from gunshot wounds while enroute to EMEDS via air ambulance.

Investigation revealed on 21 Jul 06, members of the 2/4/6 Iraqi Army reacted to a tip that Iraqi

1

FOR OFFICIAL USE ONLY
Law Enforcement Sensitive

FOR OFFICIAL USE ONLY
Law Enforcement Sensitive

insurgents were attacking a local neighborhood just southwest of Mahmudiyah. Upon making contact with the Iraqi insurgents, the Iraqi Army received small arms fire. They engaged the insurgents and returned fire, which resulted in four insurgents being wounded who were transported to the Mahmudiyah aid station. The four insurgents were medically evacuated to BIAP. During the flight, one of the insurgents succumbed to his wounds and died.

STATUTES:

N/A

EXHIBITS/SUBSTANTIATION:

Attached:

1. Agent's Investigation Report (AIR) of SA (b)(6), (b)(7)(C), 22 Jul 06, detailing initial notification, interviews of COL (b)(6), (b)(7)(C) and SPC (b)(6), (b)(7)(C), and coordination with 2LT (b)(6), (b)(7)(C) and SSG (b)(6), (b)(7)(C)
2. Certificate of Death, 21 Jul 06, detailing cause of death.
3. DA Form 3910, Death Tag, 21 Jul 06, detailing place of death.
4. U.S. Field Medical Card, not dated, detailing patient's treatment.
5. 1/502nd Infantry Regiment treatment document, 21 Jul 06, detailing patient's treatment.
6. AIR of SA (b)(6), (b)(7)(C), Aberdeen Proving Ground Resident Agency (CID), Aberdeen Proving Ground, MD, 7 Aug 06, detailing attendance of the autopsy of an unknown Iraqi National.
7. Fingerprint card of unknown Iraqi male, 4 Aug 06.
8. Compact Disc, ME 06-0665, 7 Aug 06, containing all photographic images exposed during the autopsy of the unknown Iraqi male. (USACRC copy only)
9. AIR of SA (b)(6), (b)(7)(C), 11 Oct 06, detailing receipt of Final Autopsy Report and Certificate of Death.
10. Final Autopsy Report of unknown Iraqi male, 13 Sep 06, detailing the cause and manner of death.

2

FOR OFFICIAL USE ONLY
Law Enforcement Sensitive

2

FOR OFFICIAL USE ONLY
Law Enforcement Sensitive

11. Certificate of Death pertaining to unknown Iraqi male, 7 Aug 06.

12. AIR of SA (b)(6), (b)(7)(C) Camp Bucca, Iraq, 18 Oct 06, detailing interviews of Mr. (b)(6), (b)(7)(C) and Mr. (b)(6), (b)(7)(C)

13. AIR of SA (b)(6), (b)(7)(C) Camp Cropper, Iraq, 20 Oct 06, detailing interview of Mr. (b)(6), (b)(7)(C)

14. Photographic packet (CD) comprised of five photographs.

a. Packet containing photographs 1-5 (Unknown Iraqi male).

15. Compact disc 060209.259 containing all photographic images and the originals of Exhibit 14. (USACRC and file copies only)

Not Attached:

None.

The originals of Exhibits 1, 3 through 7, 9 and 12 through 15 are forwarded with the USACRC copy of this report. The originals of 2, 8, 10 and 11 are maintained in the files of the Armed Forces Institute of Pathology (AFIP), 1413 Research Blvd, Building 102, Rockville, MD 20850.

STATUS: This is a Final Report.

FOR OFFICIAL USE ONLY
Law Enforcement Sensitive

REPORT PREPARED BY

REPORT APPROVED BY

(b)(6), (b)(7)(C), (b)(7)(F)

(b)(6), (b)(7)(C)

Special Agent

Special Agent-in-Charge

DISTRIBUTION:

Dir, USACRC, 6010 6th St, Ft Belvoir, VA 22060

CDR, 10th MP Bn (CID) (ABN), Camp Victory, IZ 09342

CDR, 3D MP GRP (CID), Ft Gillem, GA 30297

CDR, 76th MP Det (CID), 10th MP BN (CID), Camp Victory, APO AE 09342

Cdr, MNF-I, TF 134, Camp Victory, IZ 09342

CDR, USACIDC, 6010 6th Street, Fort Belvoir, VA 22060

PMO, MNC-I, ATTN: COL (b)(6), (b)(7)(C), Al Faw Palace, Camp Victory, IZ 09342

SJA, MNC-I ATTN: LTC (b)(6), (b)(7)(C), Camp Victory IZ, 09342

Cdr, 727th MP Det, Camp Victory, IZ 09342

OAFME, AFIP, 1413 Research Blvd, Bldg 102, Rockville, MD 20850

FILE

AGENT'S INVESTIGATION REPORT
CID Regulation 195-1

ROI NUMBER
0209-06-CID259-75994

PAGE 1 OF 1 PAGE

DETAILS

BASIS FOR INVESTIGATION: About 1745, 21 Jul 06, this office was notified by Sather Air Base Emergency Medical Services (EMEDS), Baghdad International Airport (BIAP), Baghdad, Iraq, of a deceased Iraqi at the EMEDS, who died from gunshot wounds during his capture.

About 1830, 21 Jul 06, SA (b)(6), (b)(7)(C) interviewed COL (MD) (b)(6), (b)(7)(C) Commander, EMEDS, who stated an unidentified Iraqi civilian was brought to the EMEDS with a fatal gunshot wound to his chest. COL (b)(6), (b)(7)(C) stated he checked the Iraqi male for signs of life and pronounced him dead at 1815, 21 Jul 06.

About 1845, 21 Jul 06, SA (b)(6), (b)(7)(C) and SA (b)(6), (b)(7)(C) interviewed SPC (b)(6), (b)(7)(C) 2nd Brigade Medical Team, Mahmudiyah, Iraq (IZ), who stated he flew with the Iraqi male from Mahmudiyah, IZ, to BIAP on a MEDIVAC. He stated he was only there as security and was not trained as a medic. SPC (b)(6), (b)(7)(C) stated four Iraqi males, to include the deceased, were brought to the Mahmudiyah Aid Center with multiple gunshot wounds by the Iraqi Army. He stated the four Iraqi males were administered first aid at the Aid Center in Mahmudiyah and were then flown to BIAP. SPC (b)(6), (b)(7)(C) believed the capturing unit was 2/4/6 Iraqi Army. SPC (b)(6), (b)(7)(C) had no further information to provide as he stated he was only placed on the MEDIVAC as a "hey you" detail and was not aware of all the details.

About 1930, 21 Jul 06, SA (b)(6), (b)(7)(C) and SA (b)(6), (b)(7)(C) obtained from 2LT (b)(6), (b)(7)(C) Operations, EMEDS, BIAP, the patient numbers of the four Iraqi males:
600-00-1350: (b)(6), (b)(7)(C), Iraqi male, multiple gunshot wounds throughout body. (Alive)
600-00-1351: Unknown Iraqi male, gunshot wound to the back, collapsed lung. (Alive)
600-00-1352: Unknown Iraqi male, gunshot wound to shoulder. (Alive)
600-00-1353: Unknown Iraqi male, gunshot wound to chest and leg. (Deceased)

About 2000, 21 Jul 06, SA (b)(6), (b)(7)(C) obtained from SGT (b)(6), (b)(7)(C), Mortuary Affairs, Sather Air Base, BIAP, Baghdad, Iraq, a Death Tag (DA Form 3910), U.S. Field Medical Card (DD Form 1380) and 1/502nd INF REG Medical documents and Certificate of Death (DA Form 2669-R) pertaining to the unidentified Iraqi male, dated 21 Jul 06, listing the cause of death as gunshot wounds. (See death tag, U.S. Field Medical Card, 1/502nd INF REG Medical documents and Certificate of Death for details)

About 0010, 22 Jul 06, SA (b)(6), (b)(7)(C) coordinated with SSG (b)(6), (b)(7)(C), Tactical Operations Center (TOC), 2nd Brigade Combat Team (BCT), 101st Airborne, Camp Striker, Iraq, who related on 21 Jul 06, members of the 2/4/6 Iraqi Army reacted to a tip Iraqi insurgents were attacking civilians southwest of Mahmudiyah, IZ. Upon contact with the insurgents, small arms fire was received and returned by members of the 2/4/6 Iraqi Army which resulted in four insurgents being wounded. The wounded were transported to the Mahmudiyah Aid Station for treatment of their wounds and later evacuated to BIAP. ///LAST ENTRY///

TYPED AGENT'S NAME AND SEQUENCE NUMBER:
SA (b)(6), (b)(7)(C), (b)(7)(F)

ORGANIZATION:
76th MP Detachment (CID),
Camp Slayer, Iraq, APO AE 09342

SIGNATURE (b)(6), (b)(7)(C)

DATE: 22 Jul 06 EXHIBIT

5

ACLU

0126 ACLU DD III (CID ROI) 3130

4 FEB 77

LAW ENFORCEMENT SENSITIVE

Exhibit(s) 2 thru 5

Page(s) 6 thru 10 referred to:

CDR U.S. Army Medical Command
Freedom of Information/Privacy Act Office
ATTN: MCFP Bldg 126 Stop 76
1216 Stanley Road 2nd Floor
Fort Sam Houston, TX 78234-5049

TAB 0209-06-01-50 75994

CERTIFICATE OF DEATH

For use of this form, see AR 190-8; the proponent agency is PMG.

INTERMENT SERIAL NUMBER

FROM:

TO:

NAME (Last, first, MI) UNKNOWN, UNKNOWN		GRADE	SERVICE NUMBER
NATIONALITY Iraqi	POWER SERVED	PLACE OF CAPTURE/INTERMENT Baghdad (b)(6)	06
PLACE OF BIRTH UNKNOWN	NAME, ADDRESS, AND RELATIONSHIP OF NEXT OF KIN UNKNOWN		DATE OF BIRTH UNKNOWN
FIRST NAME OF FATHER UNKNOWN		PLACE OF DEATH EMED, Sather AB	DATE OF DEATH (b)(6) 2006
CAUSE OF DEATH Burst wounds		PLACE OF BURIAL	DATE OF BURIAL
IDENTIFICATION OF GRAVE			

PERSONAL EFFECTS (To be filled in by Office of Deputy Chief of Staff for Personnel)

RETAINED BY DETAINING POWER FORWARDED WITH DEATH CERTIFICATE TO (Specify) FORWARDED SEPARATELY TO (Specify)

BRIEF DETAILS OF DEATH/BURIAL BY PERSON WHO CARED FOR THE DECEASED DURING ILLNESS OR DURING LAST MOMENTS (Doctor, Nurse, Minister of Religion, Fellow Internee). IF CREMATED, GIVE REASON. (If more space is required, continue on reverse side).

DO NOT WRITE IN THIS SPACE CERTIFIED A TRUE COPY	DATE (b)(6)	SIGNATURE OF MEDICAL OFFICER (b)(6)
	SIGNATURE OF COMMANDING OFFICER [Signature]	
	WITNESSES	
	SIGNATURE	ADDRESS
SIGNATURE	ADDRESS	

1. LAST NAME-FIRST NAME-MIDDLE INITIAL				2. GRADE	
				3. SOCIAL SECURITY NO. (b)(6)	
4. ORGANIZATION				U. WARD	
6. DEATH OCCURRED				7. PLACE WHERE DEATH OCCURRED	
HOUR (b)(6)	DAY (b)(6)	MO.	YEAR 06	EMERGENCY SERVICES	
AUTHORIZED SIGNATURE (b)(6)					

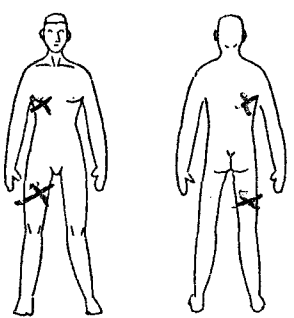
DA FORM 1 AUG 72 3910 REPLACES DA FORM 8-219, 1 MAR 63, WHICH WILL BE USED. DEATH TAG

For use of this form see, AR 40-400; the proponent agency is OTSG. ☆U.S.GPO: 2002-486-002

~~For Official Use Only~~
~~Law Enforcement Sensitive~~

0209 06 CID 259 75994

~~For Official Use Only~~
~~Law Enforcement Sensitive~~

1. LAST NAME, FIRST NAME / NOM ET PRÉNOM		RANK / GRADE	<input checked="" type="checkbox"/> MALE / HOMME	
SSN / NUMÉRO MATRICULE		SPECIALTY CODE / GPM	<input type="checkbox"/> FEMALE / FEMME	
2. UNIT / UNITÉ				
FORCE / ÉLÉMENT		NATIONALITY / NATIONALITÉ		
AT	AF/A	N/M	MCM	
BC/BC		NBI/BNC	DISEASE/MALADIE	PSYCH/PSYCH
3. INJURY / BLESSURE		AIRWAY / TRACHÉE		
FRONT / DEVANT		HEAD / TÊTE		
BACK / ARRIÈRE		<input checked="" type="checkbox"/> WOUND / BLESSURE		
		NECK/BACK INJURY / BLESSURE AU COU/AU DOS		
		BURN / BRÛLURE		
		AMPUTATION / AMPUTATION		
		STRESS / TENSION		
		OTHER (Specify) / AUTRE (Spécifier)		
4. LEVEL OF CONSCIOUSNESS / NIVEAU DE CONSCIENCE				
ALERT / ALERTE		PAIN RESPONSE / RÉPONSE À LA DOULEUR		
VERBAL RESPONSE / RÉPONSE VERBALE		UNRESPONSIVE / SANS RÉPONSE		
5. PULSE / POULS	TIME / HEURE	6. TOURNIQUET / GARROT	TIME / HEURE	
		<input type="checkbox"/> NO / NON <input type="checkbox"/> YES / OUI		
7. MORPHINE / MORPHINE	DOSE / DOSE	TIME / HEURE	8. IV / IV	
<input checked="" type="checkbox"/> NO / NON <input type="checkbox"/> YES / OUI				
9. TREATMENT / OBSERVATIONS / CURRENT MEDICATION / ALLERGIES / NBC (ANTIDOTE) TRAITEMENT / OBSERVATIONS / PRÉSENTE MEDICATION / ALLERGIES / ANTIDOTES				
Patient needs decompress GSW to chest. Patient GSW filled with Hemocon Central Venous placed at 1700 IO placed 1658 Z				
10. DISPOSITION / DISPOSITION	RETURNED TO DUTY / RETOUR À L'UNITÉ	TIME / HEURE		
	<input checked="" type="checkbox"/> EVACUATED / EVACUÉ			
	DECEASED / DÉCÉDÉ			
11. PROVIDER / UNIT / OFFICIER MÉDICALE / UNITÉ			DATE / DATE (YYMMDD)	

DD Form 1380, This form replaces previous editions of DD Form 1380 and DD Form 1380 (TEST), which are obsolete. U.S. FIELD MEDICAL CARD
DEC 91 FICHE MÉDICALE RESERVANT ÉTATS-UNIS

REGION	DIAGNOSIS, PROCEDURES and 24 hr Follow-up Recommendations	
Face		
Head & Neck (incl C-spine)		
Chest (incl T-spine)	GSW to chest (b)(6) decompressed	applied needle
Abdomen (incl L-spine)		
Pelvis		
UPPER /LOWER Extremities	GSW to (R) femur hem con and co ban applied	
Skin		
DISPOSTION DTG:	<input type="checkbox"/> EVAC to _____ <input type="checkbox"/> RTD <input type="checkbox"/> DECEASED (see below)	Evacuation Priority <input type="checkbox"/> ROUTINE <input type="checkbox"/> PRIORITY <input type="checkbox"/> URGENT

Damage Control Procedures? Y / N Hypothermic (< 34°C)? Y / N Coagulopathy? Y / N

WOUNDED BY:

US/COALITION (Nation) _____ OTHER: _____
 ENEMY
 CIVILIAN
 TRAINING
 SELF (ACCIDENT)
 SELF (NON-ACCIDENT)
 SPORTS RECREATION

1-502nd Infantry Regiment (AASLT)
 Battalion Aid Station, Forward Operating Base Mahmudiyah

#1

AUTHORITY: AR 40-66
PURPOSE: To provide a standard means of documenting all trauma care at echelons 1-3
ROUTINE USES: The "Blanket Routine Uses" set forth at the beginning of the Army compilation of systems of records notice apply.
DISCLOSURE: This is protected health information. HIPAA laws apply

MTF DESIGNATION: Number _____ **TYPE** _____ **CASUALTY NAME:** _____ **CASUALTY SSN:** _____

Arrive Date-Time Group (DTG): (b)(6) **Rank** _____ **Date of Birth** _____ **Gender** Male Female **Unit** _____

ARRIVAL METHOD: WALKED CARRIED Non-MED AIR OTHER Non-MED GND SHIP EVAC GND AMB AIR AMB
Nation US Host Nation Enemy() Coalition() **Service** Civilian Combatant Contractor USA SOF USN NGO () USMC Other USAF

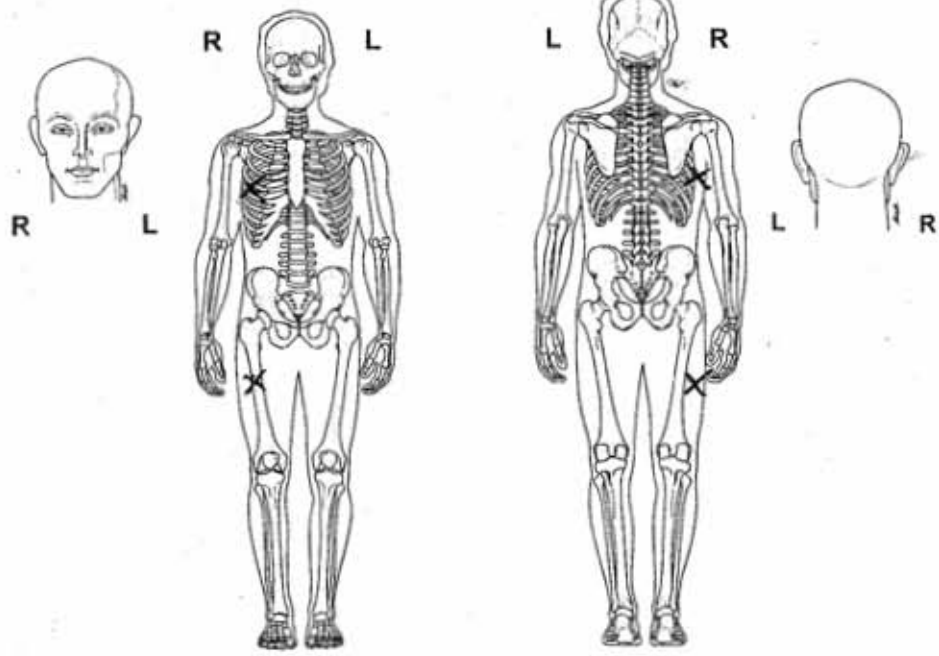
ALLERGIES: _____ **FLUIDS RECEIVED:** 500ml _____ 1000ml _____ **TIME** _____ **TRIAGE CATEGORY:** IMMEDIATE DELAYED MINIMAL EXPECTANT

MORPHINE: 5mg _____ 10mg _____ **ROUTE:** IV IM **YES/NO** _____
 5mg _____ 10mg _____ **ROUTE:** IV IM _____
 5mg _____ 10mg _____ **ROUTE:** IV IM _____
 5mg _____ 10mg _____ **ROUTE:** IV IM _____
TOTAL mg RECEIVED _____ **SODIUM CHLORIDE W/ 1G ANCEF** _____ **SODIUM CHLORIDE** _____ **LACTATED RINGERS** _____ **HEXTEND** _____ **X-RAYS TAKEN: YES/ NO** _____ **RADIOLOGIC VIEW: FX/ABNORMALITY/PATHOLOGY** _____

MECHANISM OF INJURY: GSW/BULLET BLUNT TRAUMA SINGLE FRAGMENT MULTI FRAGMENT KNIFE / EDGE BLAST MVA Chem/Rad/Nucl BURN (thermal, flash) CRUSH FALL SMOKE Inhalation HEAT COLD BITE / STING OTHER _____

TIME	
Pulse	
Temp	
B/P	
Resp	
SpO ₂	94

INJURY Description (Location, nature and size in cm)



AM Amputation BL Bleeding D Deformity H Hematoma
 AV Avulsion B Burn F Foreign Body L Laceration
 P Puncture X Fracture S Stab Wnd G Gunsh Wnd

TX & PROCEDURES:	
SUTURE	
EXTRACTION	
INTUBATED	
CRICO	
NEEDLE DECOMP	1642
Chest Tube	L R air/blood
IO line	
TOURNIQUET	Time on
	Time off
Collar / C-spine Back board	
HEMOSTATIC DEVICE	HEMCON QUICKCLOT
OXYGEN	Lite 10 min.

AGENT'S INVESTIGATION REPORT

0119-06-CID112

CID Regulation 195-1

PAGE 1 OF 1 PAGES

Basis for Investigation: About 1330, 06 Aug 06, this office was notified by SA (b)(6), (b)(7)(C) (b)(6), (b)(7)(C) Naval Criminal Investigative Service (NCIS), Office of the Armed Forces Medical Examiner (OAFME), Armed Forces Institute of Pathology (AFIP), 1413 Research Boulevard (Blvd), Building (Bldg) 102, Rockville, MD 20850, that the remains of a BTB Foreign National would be arriving at Dover Air Force Base (AFB) and the autopsy would be conducted on 07 Aug 06.

About 0830, 07 Aug 06, SA (b)(6), (b)(7)(C) attended the autopsy of an unknown Iraqi National (ME # 06-663), which was conducted by Dr. (CDR) (b)(6), (b)(7)(C) USN, Associate Medical Examiner, OAFME, AFIP, 1413 Research Blvd, Bldg 102, Rockville, MD 20850 and Dr. (CDR) (b)(6), (b)(7)(C) USNR, Deputy Medical Examiner, OAFME, AFIP, 1413 Research Blvd, Bldg 102, Rockville, MD 20850. The preliminary cause of death was opined as Multiple (2) Gunshot wounds of the Chest and Extremities and manner of death was homicide. Photographers from AFIP exposed digital photographs of the autopsy and prepared a compact disc (CD) containing all images exposed. A copy of the CD containing all images was obtained. (See Preliminary Autopsy Report (PAR) and CD for details)

STATUS: The official results of the autopsy will be documented in the Final Autopsy Report, which will be provided upon completion. /// Last Entry ///

(b)(6), (b)(7)(C), (b)(7)(F)

APG Resident Agency (CID)
APG, MD 21005

Date:
07 Aug 06

Exhibit:

FOR OFFICIAL USE ONLY

LAW ENFORCEMENT SENSITIVE

LEAVE BLANK

OFFICIAL USE ONLY
TYPE OF PRINT AND INFORMATION IN THIS SECTION
LAST NAME FIRST NAME

FBI LEAVE BLANK

019-06-0002

STATE USAGE

ALIASES

CONTRIBUTOR

OR I

DUPBIMFEE

FBI
DISASTER SQUAD

DATE OF BIRTH DOB
Month Day Year

SIGNATURE OF PERSON FINGERPRINTED

THIS DATA MAY BE COMPUTERIZED IN LOCAL, STATE AND NATIONAL FILES

DATE ARRESTED OR RECEIVED DOA

SEX

RACE

HGT.

WGT.

EYES

HAIR

PLACE OF BIRTH POB

DATE

SIGNATURE OF OFFICIAL TAKING FINGERPRINTS

YOUR NO. OCA

LEAVE BLANK

CHARGE

FBI NO. FBI

CLASS:

SID NO. SID

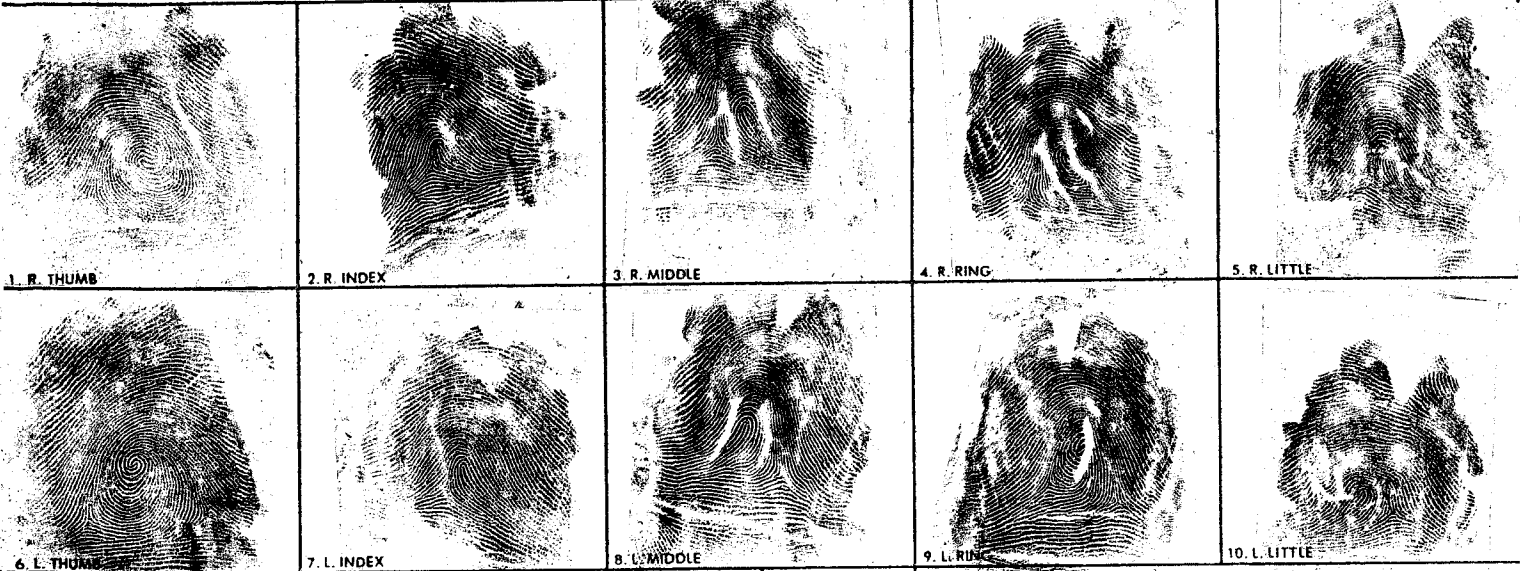
REF:

SOCIAL SECURITY NO. SOC

NCIC CLASS - FPC

FINAL DISPOSITION

CAUTION



LEFT FOUR FINGERS TAKEN SIMULTANEOUSLY

L. THUMB

R. THUMB

RIGHT FOUR FINGERS TAKEN SIMULTANEOUSLY

Dover AFB Port Mortuary



Incident : OIF

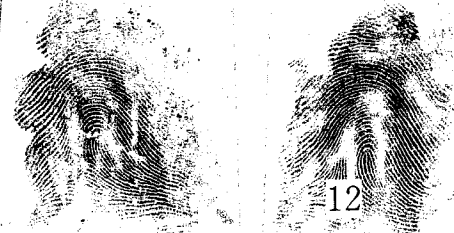Remains/Case #: 7200

Recovery/TC #:

Process Date: 04 Aug 06 ME #:

ACLU-RDI 5866 p. 13

10-L-0156



(ROI) 3138

AGENT'S INVESTIGATION REPORT

ROI NUMBER

0209-06-CID259-75994

CID Regulation 195-1

PAGE 1 OF 1 PAGES

DETAILS

About 1015, 11 Oct 06, SA (b)(6), (b)(7)(C) received the Final Autopsy Report and Death Certificate from SA (b)(6), (b)(7)(C). The report stated the cause of death was multiple gunshot wounds of the chest and right lower extremity and the manner of death was homicide. (See Autopsy Report and Death Certificate for details)
/// LAST ENTRY ///

TYPED AGENT'S NAME AND SEQUENCE NUMBER

SIGNATURE: (b)(6), (b)(7)(C)

DATE:

11 Oct 06

CID FORM 94-E

FO

EXHIBIT 9

1 OCT 95

LAW ENFORCEMENT SENSITIVE
PROTECTIVE MARKING IS EXCLUDED FROM
AUTOMATIC TERMINATION (Para 13, AR 340-16)
(When Data Is Entered)

ROI 06-CID259-75994-5H6

Exhibit(s): 10 and 11

Page(s): 15 thru 24

Referred to:

**Commander
U.S. Army Medical Command
Attn: FOIA Office, Stop 76
1216 Stanley Road 2D FL
Fort Sam Houston, Texas 78234-5049**



ARMED FORCES INSTITUTE OF PATHOLOGY
Office of the Armed Forces Medical Examiner
1413 Research Blvd., Bldg. 102
Rockville, MD 20850
1-301-319-0000



AUTOPSY EXAMINATION REPORT

Name: BTB Foreign National	Autopsy No.: I (b)(6)
SSAN: (b)(6)	AFIP No.: (b)(6)
Date of Birth: Unknown	Rank: Civilian
Date of Death: (b)(6) 2006	Place of Death: Iraq
Date/Time of Autopsy: 07 AUG 2006/0900	Place of Autopsy: Port Mortuary
Date of Report: 13 SEP 2006	Dover AFB, Dover, DE

Circumstances of Death: This unidentified civilian foreign national came under small arms fire in Iraq. By report, he was treated by medics in the field and succumbed to his injuries prior to reaching a medical treatment facility

Authorization for Autopsy: Office of the Armed Forces Medical Examiner, IAW 10 USC 1471

Identification: Unidentified; BTB foreign national per investigative report

CAUSE OF DEATH: Multiple (2) gunshot wounds of the chest and right lower extremity

MANNER OF DEATH: Homicide

FOR OFFICIAL USE ONLY and may be exempt from mandatory disclosure under FOIA. DoD 5400.7R, "DoD Freedom of Information Act Program", DoD Directive 5230.9, "Clearance of DoD Information for Public Release", and DoD Instruction 5230.29, "Security and Policy Review of DoD Information for Public Release" apply.

~~For Official Use Only~~
~~Law Enforcement Sensitive~~

EXHIBIT 10

FINAL AUTOPSY DIAGNOSES:

- I. Gunshot wound of the chest
 - A. Entrance: right upper chest, 3/16-inch circular wound with an eccentric abrasion collar along the 12 to 6 o'clock border measuring up to 3/16-inch at the 3 o'clock position, located 14 1/2-inches below the top of the head (5-inches below the top of the shoulder) and 4 3/4-inches to the right of the anterior midline of the trunk, no evidence of gunpowder stippling or soot deposition on the surrounding skin
 - B. Injuries: skin, subcutaneous tissue, muscle, subcutaneous tissue and skin
 - C. Exit: right side of the chest, vertically oriented oval wound measuring 1 1/4-inches x 1/2-inch, located 19 1/2-inches below the top of the head (11 1/2-inches below the top of the shoulder) and 8 1/4-inches to the right of the posterior midline of the trunk
 - D. No bullet or bullet fragments are recovered
 - E. Direction: Front to back, left to right and downward
 - F. Associated injuries: multiple rib fractures (lateral right #3-5), right hemothorax (200-milliliters), laceration of the hilar aspect of the upper lobe of the right lung, bilateral pulmonary edema (right - 700 grams, left - 630 grams)

- II. Gunshot wound of the right thigh
 - A. Entrance: proximal posterior right thigh, horizontally oriented oval wound measuring 1/4 x 1/8-inch with an eccentric abrasion collar up to 1/16-inch at the 9 o'clock margin, located 31 1/2-inches above the heel and 3 1/4-inches to the right of the posterior midline of the right leg in the anatomic position, no evidence of gunpowder stippling or soot deposition on the surrounding skin
 - B. Injuries: skin, subcutaneous tissue, muscle, major branches of the proximal femoral artery, proximal right femur (comminuted fracture), muscle, subcutaneous tissue and skin
 - C. Exit: anterior right thigh, obliquely oriented 1 3/4 x 1-inch lacerated exit wound oriented along the 4 to 11 o'clock axis located 34-inches above the heel in the midline of the limb in the anatomic position
 - E. No bullet or bullet fragments are recovered
 - F. Direction: back to front, right to left, and slightly upward
 - G. Associated injuries: bleeding into the wound path

- III. Other traumatic injuries
 - A. Abrasion on the proximal lateral left thigh, 1 1/4 x 1/4-inches
 - B. Separate layerwise dissections of the extremities, neck and torso reveal no evidence of additional recent or remote trauma

~~For Official Use Only~~

EXHIBIT 10

IV. Natural disease diagnoses

- A. Left hydrocele
- B. Scant pleural adhesions, bilaterally

V. Evidence of medical intervention

- A. Oxygen mask
- B. Unused, coiled angiocatheter taped to the upper right chest
- C. Intraosseous catheter in the upper sternum
- D. Plastic bag containing instructions for use of the intraosseous catheter taped to the upper right chest
- E. Angiocatheter in place in the upper left chest, entering the thoracic cavity
- F. Asherman chest seal covering the wound on the lateral right chest
- G. Double lumen catheter with 6% Hetastarch in normal saline (500 – milliliters) sutured in the left groin and secured with tape
- H. Foam packing material in wound of anterior right thigh, 2 ½ x 1 ½ x 1-inches
- I. Tourniquet applied to right thigh, located distal to wounds on right thigh
- J. Blood soaked gauze dressing with circumferential ace wrap distal to wound and tourniquet on right thigh

VI. Post-mortem changes consist of greenish discoloration and minimal to moderate autolysis and decomposition of solid organs and the brain

VII. Toxicology results

- A. Volatiles: The blood was examined for the presence of ethanol at a cutoff of 20 mg/dl. No ethanol was detected.
- B. The urine was screened for amphetamine, antidepressants, antihistamines, barbiturates, benzodiazepines, cannabinoids, chloroquine, cocaine, dextromethorphan, lidocaine, narcotic analgesics, opiates, phencyclidine, phenothiazines, sympathomimetic amines and verapamil by gas chromatography, color test or immunoassay. Lidocaine was detected in the urine by gas chromatography and confirmed by gas chromatography/mass spectrometry.

~~For Official Use Only~~

EXHIBIT 10

EXTERNAL EXAMINATION

The body is that of a well-developed, well-nourished appearing, muscular male, 74-inches in length and weighing 154-pounds whose appearance is that of a young adult male. The body is cold. Rigor is present to an equal degree in all extremities. Lividity is present and fixed on the posterior surface of the body, except in areas exposed to pressure. Evidence of mild decomposition consists of light green discoloration of the abdominal skin.

The scalp is covered with short straight black hair in a normal distribution. Facial hair consists of black stubble and a trim black moustache. The irides are brown, and the pupils are round and equal in diameter. The corneae are clear and the sclera white. The conjunctivae are unremarkable. The external auditory canals are free of foreign materials and abnormal secretions. The ears are unremarkable. The nares are patent and the lips are atraumatic. The nose and maxillae are palpably stable. The teeth are natural, in fair condition with a few remotely absent molars.

The neck is straight, and the trachea is midline and mobile. The chest is symmetric. The abdomen is flat. The fingernails are intact. There is a vertically oriented, hypopigmented 2-inch linear scar on the right upper chest. The genitalia are those of a normal adult circumcised male. The testes are descended and free of masses. Pubic hair is present in a normal distribution. The buttocks and anus are unremarkable.

The upper and lower extremities are symmetric, without clubbing, edema or non-traumatic deformity.

CLOTHING AND PERSONAL EFFECTS

No clothing items or personal effects accompany the body at the time of autopsy.

MEDICAL INTERVENTION

Evidence of medical intervention consists of:

- Oxygen mask
- Unused, coiled angiocatheter taped to the upper right chest
- Intraosseous catheter in the upper sternum
- Plastic bag containing instructions for use of the intraosseous catheter taped to the upper right chest
- Angiocatheter in place in the upper left chest, entering the thoracic cavity
- Asherman chest seal covering the wound on the lateral right chest
- Double lumen catheter with 6% Hetastarch in normal saline (500 – milliliters) sutured in the left groin and secured with tape
- Foam packing material in wound of anterior right thigh, 2 ½ x 1 ½ x 1-inches
- Tourniquet applied to right thigh, located distal to wounds on right thigh
- Blood soaked gauze dressing with circumferential ace wrap distal to wound and tourniquet on right thigh

For Official Use Only

EXHIBIT 10
18

RADIOGRAPHS

A complete set of postmortem radiographs is obtained and demonstrates the following:

- Comminuted fracture of the right femur
- Multiple lateral right rib fractures, ribs #3-5

EVIDENCE OF INJURY

The ordering of the following injuries is for descriptive purposes only, and is not intended to imply order of infliction or relative severity. All wound pathways are given relative to standard anatomic position.

I. Gunshot wound of the chest:

A gunshot entrance wound is on the right upper chest located 14 ½-inches below the top of the head (5-inches below the top of the shoulder) and 4 ¼-inches to the right of the anterior midline of the trunk. The circular wound measures 3/16-inch with an eccentric marginal abrasion along the 12 to 6 o'clock border measuring up to 3/16-inch on the 3 o'clock border. Soot or gunpowder stippling are not present in the wound or on the surrounding skin. The wound path perforates skin, subcutaneous tissue, muscle, subcutaneous tissue and skin. The bullet exited the right side of the chest via a 1 ¼ x ½-inch vertically oriented oval exit wound located 19 ½-inches below the top of the head (11 ½-inches below the top of the shoulder) and 8 ¼-inches to the right of the posterior midline of the back. No bullet or fragments are recovered. The wound path is directed front to back, left to right and downward. Associated with the wound path is bleeding into the wound tract, multiple rib fractures (lateral right #3-5), right hemothorax (200-milliliters), laceration of the hilar aspect of the upper lobe of the right lung (1 x ½-inches), bilateral pulmonary edema (right - 700 grams, left - 630 grams).

II. Gunshot wound to the right thigh:

A gunshot entrance wound is on the proximal posterior right thigh located 31 ½-inches above the heel and 3 ¼-inches to the right of the posterior midline of the right leg in the anatomic position. The horizontally oriented ovoid wound measures ¼ x 1/8-inch with an eccentric marginal abrasion measuring up to 1/16-inch at the 9 o'clock margin. Soot or gunpowder stippling are not present in the wound or on the surrounding skin. The wound path perforates skin, subcutaneous tissue, muscle, major branches of the proximal femoral artery, proximal right femur (comminuted fracture), muscle, subcutaneous tissue and skin. The bullet exited the anterior right thigh via an obliquely oriented (along the 4 to 11 o'clock axis) 1 ¼ x 1-inch lacerated exit wound located 34-inches above the heel and in the midline of the leg in the anatomic position. No bullet or fragments were recovered. The wound path was directed back to front, right to left, and slightly upward. Associated with the wound path is bleeding into the wound tract.

~~For Official Use Only~~

EXHIBIT 10
19

III. Other traumatic injuries

There is a 1 ¼ x ¼-inch abrasion on the proximal lateral left thigh. Separate layerwise dissections of the extremities, neck and torso reveal no evidence of additional recent or remote trauma.

INTERNAL EXAMINATION

HEAD:

The galeal and subgaleal soft tissues of the scalp are free of injury. The calvarium is intact, as is the dura mater beneath it. Clear cerebrospinal fluid surrounds the 1380 gm brain, which has unremarkable gyri and sulci. Coronal sections demonstrate sharp demarcation between white and grey matter, without hemorrhage or contusive injury. The ventricles are of normal size. The basal ganglia, brainstem, cerebellum, and arterial systems are free of injury or other abnormalities. There are no skull fractures. The atlanto-occipital joint is stable.

NECK:

The anterior strap muscles of the neck are homogenous and red-brown, without hemorrhage. The thyroid cartilage and hyoid are intact. The larynx is lined by intact white mucosa. The thyroid is symmetric and red-brown, without cystic or nodular change. The tongue is free of bite marks, hemorrhage, or other injuries.

BODY CAVITIES:

Injuries to the chest have been described in "Evidence of Injury". The ribs, sternum, and vertebral bodies are visibly and palpably intact. No excess fluid is in the pericardial, peritoneal or left pleural cavities. The organs occupy their usual anatomic positions.

RESPIRATORY SYSTEM:

Injuries to the right lung have been described in "Evidence of Injury". The right and left lungs weigh 700 and 630-grams, respectively. The external surfaces are smooth and deep red-purple with loose inter-lobar adhesions. The pulmonary parenchyma is diffusely congested and edematous, exuding moderate amounts of bloody fluid. The pulmonary arteries are normally developed, patent and without thrombus or embolus. No mass lesions or areas of consolidation are present.

CARDIOVASCULAR SYSTEM:

The 330-gram heart is contained in an intact pericardial sac. The epicardial surface is smooth, with minimal fat investment. The coronary arteries are present in a normal distribution, with a right-dominant pattern. Cross sections of the vessels show no evidence of significant atherosclerosis or thrombosis. The myocardium is homogenous, red-brown, and firm. The valve leaflets are thin and mobile. The walls of the left and right ventricles are 1.1 and 0.3-centimeters thick, respectively. The endocardium is smooth and glistening. The aorta gives rise to three intact and patent arch vessels. The renal and mesenteric vessels are unremarkable. The venae cavae and its major tributaries return to the heart in the usual distribution and are free of thrombi.

~~For Official Use Only~~

EXHIBIT 10
20

LIVER & BILIARY SYSTEM:

The 1180-gram liver has an intact, smooth capsule and a sharp anterior border. The parenchyma is tan-brown and congested, with the usual lobular architecture. No mass lesions or other abnormalities are seen. The gallbladder contains 10-milliliters of green-black bile and no stones. The mucosal surface is green and velvety. The extrahepatic biliary tree is patent.

SPLEEN:

The 220-gram spleen has a smooth, intact, red-purple capsule. The parenchyma is maroon and congested, with distinct Malpighian corpuscles.

PANCREAS:

The pancreas is firm and yellow-tan, with the usual lobular architecture and exhibits signs of early decomposition. No mass lesions or other abnormalities are seen.

ADRENALS:

The right and left adrenal glands are symmetric, with bright yellow cortices and grey medullae. No masses or areas of hemorrhage are identified.

GENITOURINARY SYSTEM:

The right and left kidneys weigh 110 and 90-grams, respectively. The external surfaces are intact and smooth. The cut surfaces are red-tan and congested, with uniformly thick cortices and sharp corticomedullary junctions. The pelves are unremarkable and the ureters are normal in course and caliber. White bladder mucosa overlies an intact bladder wall. The bladder contains approximately 20-milliliters of clear yellow urine. The prostate is normal in size, with lobular, yellow-tan parenchyma. The seminal vesicles are unremarkable. The testes are free of mass lesions or contusions. There is a left hydrocele.

GASTROINTESTINAL TRACT:

The esophagus is intact and lined by smooth, grey-white mucosa. The stomach contains approximately 500-milliliters of thick tan fluid containing partially digested food. The gastric wall is intact. The duodenum, loops of small bowel, and colon are unremarkable. The appendix is present.

ADDITIONAL PROCEDURES

- Documentary photographs are taken by OAFME staff photographers
- Specimens retained for toxicological testing and/or DNA identification are: cavity blood, vitreous fluid, urine, gastric contents, bile, spleen, liver, lung, kidney, brain, adipose tissue, and psoas muscle.
- Full body radiographs are obtained and demonstrate the above findings.
- Selected portions of organs are retained in formalin, without preparation of histological slides

~~For Official Use Only~~

EXHIBIT 10

- Separate layerwise dissections of the extremities, neck and torso reveal no evidence of additional recent or remote trauma
- The dissected organs are forwarded with the body
- Personal effects are released to the mortuary affairs representatives.
- Identifying body marks consist of a well-healed linear scar on the upper right chest

MICROSCOPIC EXAMINATION

Selected portions of organs are retained in formalin, without preparation of histologic slides.

OPINION

This unknown adult male foreign national (U06-06-63), died as the result of multiple (2) gunshot wounds of the chest and right lower extremity. A gunshot wound to the chest (wound 'I') injured ribs and the right lung without entering the thoracic cavity. A gunshot wound to the right thigh (wound 'II') fractured the right femur and lacerated (tore) major blood vessels of the right lower extremity likely causing exsanguination. Neither of the gunshot wounds have evidence of close range fire. No bullets or fragments are recovered from the wound paths. Postmortem analysis of the body fluids shows no evidence of ethanol and screened illicit drugs of abuse. The presence of lidocaine is consistent with the reported emergency medical intervention.

The manner of death is homicide.

(b)(6)

(b)(6) Medical Examiner

(b)(6)

(b)(6) Medical Examiner (b)(6)

~~For Official Use Only~~

CERTIFICATE OF DEATH (OVERSEAS)

Acte de décès (D'Outre-Mer)

0209 06 CID 259 75994

NAME OF DECEASED (Last, First, Middle) Nom du décédé (Nom et prénoms) U060663, U060663,		GRADE Grade	BRANCH OF SERVICE Arme Civilian	SOCIAL SECURITY NUMBER Numéro de l'Assurance Sociale (b)(6)
ORGANIZATION Organisation		NATION (e.g. United States) Pays Iraq	DATE OF BIRTH Date de naissance	<input checked="" type="checkbox"/> MALE <input type="checkbox"/> FEMALE
RACE Race	MARITAL STATUS État Civil		RELIGION Culte	
<input type="checkbox"/> CAUCASOID Caucasique	<input type="checkbox"/> SINGLE Célibataire	<input type="checkbox"/> DIVORCED Divorcé	<input type="checkbox"/> PROTESTANT Protestant	<input checked="" type="checkbox"/> OTHER (Specify) Autre (Spécifier)
<input type="checkbox"/> NEGROID Nègre	<input type="checkbox"/> MARRIED Marié	<input type="checkbox"/> SEPARATED Séparé	<input type="checkbox"/> CATHOLIC Catholique	
<input checked="" type="checkbox"/> OTHER (Specify) Autre (Spécifier)	<input type="checkbox"/> WIDOWED Veuf		<input type="checkbox"/> JEWISH Juif	
NAME OF NEXT OF KIN Nom du plus proche parent		RELATIONSHIP TO DECEASED Parenté du décédé avec le sus		
STREET ADDRESS Domicile à (Rue)		CITY OR TOWN OR STATE (include ZIP Code Ville (Code postal compris)		
MEDICAL STATEMENT Déclaration médicale				
CAUSE OF DEATH (Enter only one cause per line) Cause du décès (N'indiquer qu'une cause par ligne)				INTERVAL BETWEEN ONSET AND DEATH Intervalle entre l'attaque et le décès
DISEASE OR CONDITION DIRECTLY LEADING TO DEATH ¹ Maladie ou condition directement responsable de la mort.		Multiple (2) gunshot wounds of the chest and extremities		Minutes
ANTECEDENT CAUSES Symptômes précurseurs de la mort.	MORBID CONDITION, IF ANY, LEADING TO PRIMARY CAUSE Condition morbide, s'il y a lieu, menant à la cause primaire			
	UNDERLYING CAUSE, IF ANY, GIVING RISE TO PRIMARY CAUSE Condition morbide, s'il y a lieu, menant à la cause primaire			
OTHER SIGNIFICANT CONDITIONS ² Autres conditions significatives ²				
MODE OF DEATH Condition de décès	AUTOPSY PERFORMED Autopsie effectuée <input checked="" type="checkbox"/> YES Oui <input type="checkbox"/> NO Non		CIRCUMSTANCES SURROUNDING DEATH DUE TO EXTERNAL CAUSES Circonstances de la mort suscitées par des causes extérieures	
<input type="checkbox"/> NATURAL Mort naturelle	MAJOR FINDINGS OF AUTOPSY Conclusions principales de l'autopsie			
<input type="checkbox"/> ACCIDENT Mort accidentelle				
<input type="checkbox"/> SUICIDE Suicide	NAME OF PATHOLOGIST Nom du pathologiste (b)(6)			
<input checked="" type="checkbox"/> HOMICIDE Homicide	SIGNATURE Signature	DATE Date (b)(6) 2006	AVIATION ACCIDENT Accident à Avion <input type="checkbox"/> YES Oui <input checked="" type="checkbox"/> NO Non	
DATE OF DEATH (day, month, year) Date de décès (le jour, le mois, l'année) (b)(6) 2006		PLACE OF DEATH Lieu de décès Iraq		
I HAVE VIEWED THE REMAINS OF THE DECEASED AND DEATH OCCURRED AT THE TIME INDICATED AND FROM THE CAUSES AS STATED ABOVE. J'ai examiné les restes mortels du dé funt et je conclus que le décès est survenu à l'heure indiquée et à la suite des causes énumérées ci-dessus.				
NAME OF MEDICAL OFFICER Nom du médecin militaire ou du médecin sanitaire (b)(6)		TITLE OR DEGREE Titre ou diplôme (b)(6)		
GRADE Grade (b)(6)		INSTALLATION OR ADDRESS Installation ou adresse Dover AFB, Dover DE		
DATE Date		SIGNATURE Signature		

DD FORM 1 APR 77 2064

REPLACES DA FORM 3565, 1 JAN 72 AND DA FORM 3565-R(PAS), 26 SEP 75, WHICH ARE OBSOLETE.

~~For Official Use Only~~
~~Law Enforcement Sensitive~~

EXHIBIT 11
23

DISPOSITION OF REMAINS			
NAME OF MORTICIAN PREPARING REMAINS	GRADE	LICENSE NUMBER AND STATE	OTHER
INSTALLATION OR ADDRESS	DATE	SIGNATURE	
NAME OF CEMETERY OR CREMATORY	LOCATION OF CEMETERY OR CREMATORY		
TYPE OF DISPOSITION		DATE OF DISPOSITION	
REGISTRATION OF VITAL STATISTICS			
REGISTRY (Town and Country)	DATE REGISTERED	FILE NUMBER	
		STATE	OTHER
NAME OF FUNERAL DIRECTOR	ADDRESS		
SIGNATURE OF AUTHORIZED INDIVIDUAL			

DD FORM 2064, APR 1977 (BACK)

USAPA V1.00

~~For Official Use Only~~
~~Law Enforcement Sensitive~~

EXHIBIT 11

AGENT'S INVESTIGATION REPORT

CID Regulation 195-1

ROI NUMBER

UZ09-06-CID259-75994

0099-06-CID579

PAGE 1 OF 1

DETAILS

BASIS FOR INVESTIGATION: On 17 Oct 06, this office received a Request For Assistance (RFA) from the 76th Military Police Detachment (CID), Camp Slayer, Baghdad, Iraq, APO AE 09342. It was requested this office locate and interview Detainee Oday Abdul Khudiyir KARIM, Internment Serial Number (ISN) (b)(6), (b)(7)(C) and Detainee Thia Kafil JASSIM, ISN (b)(6), (b)(7)(C) who were detained at Camp Bucca, Iraq (CBI) regarding the identification of an unknown Iraqi male.

At 0900, 18 Oct 06, SA (b)(6), (b)(7)(C) reviewed the Detainee Reporting System (DRS) and obtained detainee information sheets on Detainee (b)(6), (b)(7)(C) revealing he was being detained in Compound 17C, CBI and Detainee JASSIM revealing he was being detained in Compound 7, CBI. (See Detainee Information Sheets for details)

At 1048, 18 Oct 06, SA (b)(6), (b)(7)(C) and Mr. (b)(6), (b)(7)(C) this office, interviewed Detainee JASSIM. Detainee JASSIM was shown the picture which was sent with this RFA and asked if he knew who the man was. Detainee JASSIM stated he did not know who the man in the photo was.

At 1052, 18 Oct 06, SA (b)(6), (b)(7)(C) and Mr. (b)(6), (b)(7)(C) interviewed Detainee KARIM. Detainee KARIM was shown the picture which was sent with this RFA and asked if he knew who the man was. Detainee KARIM stated he did not know who the man in the photo was. He stated he was captured at home by the Iraqi Army and had been shot a few days prior by thieves who stole his car.

At 1510, 18 Oct 06, SA (b)(6), (b)(7)(C) sent the first information report to the requesting office who stated they did not require any further investigative activities.

STATUS: This investigation is closed in the files of this office. All requested investigative activity has been completed.

//////////////////////////////////////LAST ENTRY//////////////////////////////////////

TYPE AGENT'S NAME AND SEQUENCE NUMBER SA (b)(6), (b)(7)(C), (b)(7)(F)		21 st MP DET (CID) (FWD) Camp Bucca CID Camp Bucca, IZ APO AE 09375	
SIGNATURE (b)(6), (b)(7)(C)		DATE 18 Oct 06	EXHIBIT 12

CID FORM

USE ONLY LAW ENFORCEMENT SENSITIVE

AGENT'S INVESTIGATIVE REPORT

ROI NUMBER 0121-06-CID789/0209-06-CID259-75994

CID Regulation 195-1

Page 1 of 1 pages

BASIS FOR INVESTIGATION:

About 1327, 17 Oct 06, this office received a Request For Assistance (RFA) (0209-06-CID259-75994) from the 76th Military Police Detachment (CID), Camp Slayer, Baghdad, Iraq APO AE 09342 to interview Mr. Hamid Najem MAHDI, Internment Serial Number (ISN) (b)(6), (b)(7)(C) and determine if he knows the identity of the Local Iraqi National who was shot and later died from his injuries during an active engagement against Iraqi Army Forces the day of their apprehension.

About 1005, 20 Oct 06, SA (b)(6), (b)(7)(C) with the assistance of Mr. (b)(6), (b)(7)(C) Interpreter, L3 Communications, Camp Cropper, Baghdad, Iraq (CCI), interviewed Mr. MAHDI and showed him a picture of the Local Iraqi National who died. Mr. MAHDI stated he did not know the individual in the picture. Mr. MAHDI stated he was in his residence when Iraqi Army Forces entered his residence and shot him. Mr. MAHDI stated he was by himself and does not know of anyone else who was arrested with him. SA (b)(6), (b)(7)(C) assured Mr. MAHDI that he was not going to be negatively effected by giving out the information of the individual in the picture he was shown. Mr. MAHDI adamantly maintained that he did not know who the individual in the picture was nor did he know of anyone else being apprehended with him. Mr. MAHDI reiterated he had been shot in his residence and that he was alone when it occurred.

STATUS: This investigation is closed in the files of this office. All requested investigative activity has been completed. ///Last Entry///

TYPED NAME SEQUENCE NUMBER SA (b)(6), (b)(7)(C)		ORGANIZATION 76 TH MP Det (CID)(FWD)(-), CCI, APO AE 09342
SIG (b)(6), (b)(7)(C)	DATE 20 Oct 06	EXHIBIT 113

CID FORM 94-E
(Automated)

FOR OFFICIAL USE ONLY
Law Enforcement Sensitive
PROTECTIVE MARKING IS EXCLUDED FROM
AUTOMATIC TERMINATION (Para 13, AR 34-16)